

Ayurvedic management in cerebellar ataxia (Mastulungakshaya) : A case study

Sunilkumar S. Yadav^{1*}, Ashwini V. Mandle², Sachin G. Tike³

1. PG Scholar (Agadtantra Evum Vidhivaidyak),
2. PG Scholar (RasShastra Evum Bhaishjaya Kalpana),
3. Assistant Professor & In-charge H.O.D. Of Panchakarma,

Govt. Ayurved College, Osmanabad, Maharashtra, India

*Corresponding author: Mob. No. 7208285867 Email- [iamdr.sky@gmail.com](mailto:iandr.sky@gmail.com)

ABSTRACT:-

Introduction- Cerebellar Ataxia is a form of ataxia originating in cerebellum. Affected patients shows symptoms such as; unsteadiness, loss of balance; leading to functional limitations and worsened quality of life. In cerebellar ataxia progressive atrophy of cerebellum occurs. This can be compared with *Mastulungakshaya* in Ayurveda. **Case Presentation-** A 50 years male patient having six years history of progressive unsteadiness, loss of balance during walking so walks with support, slurred speech, affected grip of upper limbs; admitted in *Panchakarma* ward. On the basis of clinical features and investigation reports of MRI and CT of the brain; diagnosis done was 'Cerebellar ataxia'. **Management And Outcome-** *Acharya Chakrapani* told that *Mastishkya* as *Shirogat Sneha* (*Charaka Sharirasthana* 7/15) and atrophy means *Kshaya of Shirogat Sneha*. Patient was treated according to above principle; *Bruhana Chikitsa* along with *Panchakarmas* like *Basti, Shirodhara, Shirobasti, Nasya, Karnapuran, Sarvang Dhara* was done. Significant improvements were seen in clinical

features. Patient is now able to walk without support, he can hold pen and can write. In MRI of the brain there was no further atrophy in cerebellum noted. **Discussion-** In the present case, already damaged part was not recovered but the further progressive damage was prevented. Also, there was significant improvement in clinical features. *Ayurveda* suggests *Vyadhiviparit Chikitsa* i.e. *Bruhana Chikitsa* in *Kshaypradhana Vyadhi*. Thus, *Vyadhinidan* (Diagnosis) according to *Ayurvedic Sidhhanta* and treating them accordingly may be helpful in many neurological disorders.

KEYWORDS:- Cerebellar Ataxia, *Mastulungakshaya*, *Vyadhiviparit Chikitsa*, *Mastishkya*, Cerebellum, *Panchakarma*.

INTRODUCTION:-

Cerebellar Ataxia is a form of ataxia originating in cerebellum. Affected patients shows symptoms such as; unsteadiness, loss of balance; leading to functional limitations and worsened quality of life. In cerebellar ataxia progressive atrophy of cerebellum

occurs. There are many causes of cerebellar ataxia CNS vasculitis, multiple sclerosis, infection, bleeding, infarction, tumors, direct injury, toxins (e.g., alcohol), genetic disorders.^[1] The etiology of cerebellar degeneration is vast and often complex, and requires neuroimaging, lab assessments, and a thorough family history to delineate its cause.^[2]

Clinical signs of cerebellar ataxia are;

- I. Dysmetria
- II. Dyssynergia
- III. Kinetic tremor^[3]

As there is no direct reference of cerebral ataxia in *Ayurvedic Samhitas*; So scattered reference of this *Anukta Vyadhi* is collected from *Samhitas*.

According to *Acharya Dalhana* shape of brain is like freezed butter (Ghee).^[4]

शिरसो बलाधानं स्त्यानघृताकार
मस्तुलुङ्ग उच्यते II

सु.चि. २/७० डल्हण

Similar explanation is also given *Acharya Sushruta* in *Sutrasthana* in *Kruta-Akrutya Adhyaya*^[5]

अर्धविलिन घृताकरो मस्तकमज्जा II
सु.सु. २३/१२

Cerebellum is a part mid brain so its atrophy can be compared with *Mastulungakshaya/ Majjakshaya* in *Ayurveda*.

Acharya Vagbhata stated *Bhrama* as a *Lakshana* of *Majjakshaya* which can be co related with loss of balance in cerebral ataxia.^[6]

मज्जाक्षय- अस्थनां मज्जनि सौषिर्यं
भ्रमस्तिमिरदर्शनम् II वा.सु. ११/१९

By studying above references and *Yukti Pramana* a case of cerebellar ataxia (*Mastulungakshaya*) was treated by *Panchakarma*.

MATERIAL & METHODS :-

Various reference have been collected from available *Ayurvedic* text and their commentaries, modern text and related websites have been searched.

CASE PRESENTATION :-

A 50 years male patient teacher by occupation was registered from OPD with registration no. 12240 to department of *Panchkarma*, Government Ayurveda hospital, Osmanabad; having six years history of progressive unsteadiness, loss of balance during walking so walks with support, slurred speech, affected grip of upper limbs.

HISTORY OF PRESENT ILLNESS :-

In 2011, Patient had complaints of loss of balance during walking and taken allopathic medication for the same. Progressively there was increase in severity of symptoms also developed; slurred speech & grip of upper limb affected. On examination, reflexes were symmetrical; berg balance scale (scale developed to measure static and dynamic balance) was 24.

PAST HISTORY :-

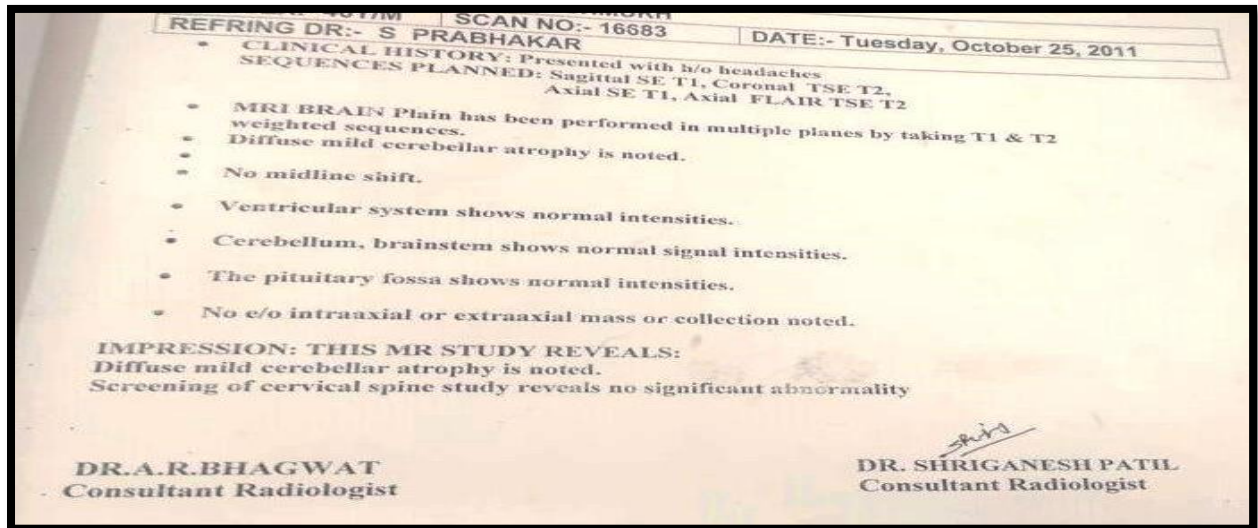
Patient had a history of stress due to work issue.

INVESTIGATION REPORTS :-

1. 25/10/2011
- I. Routine blood investigations – WNL
- II. Thyroid Function Test - WNL

III. MRI of Brain 25/10/2011 –
Diffuse mild cerebellar atrophy
noted. Ventricle shows normal

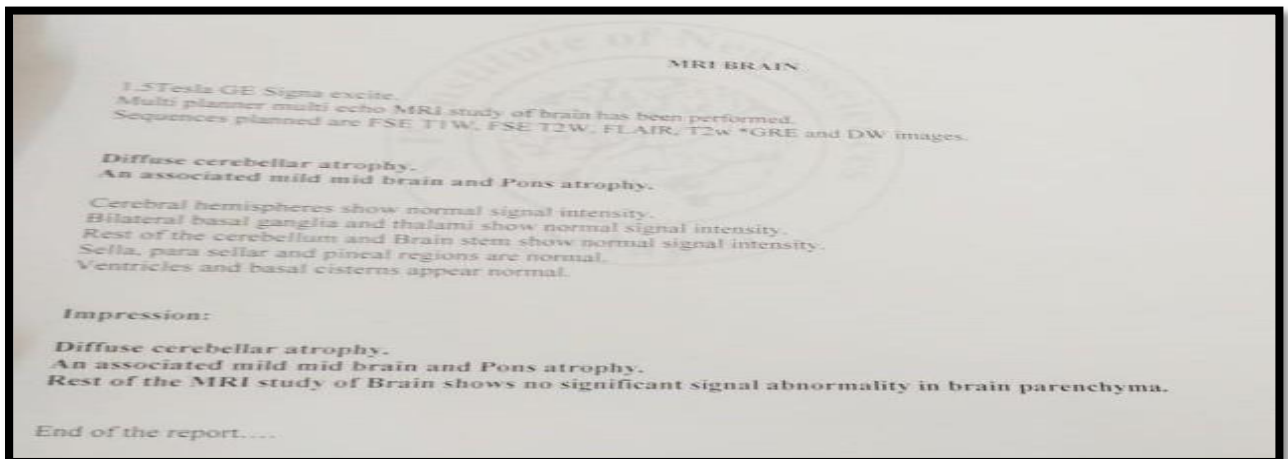
intensities. No e/o intraaxial or
extraaxial mass noted.



2. 29/06/2012

I. MRI of brain - Diffuse
cerebellar atrophy
associated with mild mid

brain and pons atrophy.
Rest of MRI study of brain
shows no significant
signal abnormality



DIAGNOSIS:-

On the basis of above clinical features and investigation reports of MRI; diagnosis made was 'Cerebellar ataxia'. Also according to *Ayurveda* the present condition of the patient can be attributed to *MajjaKshaya* with vitiation of *Vata* leading to progressive unsteadiness and slurred speech.

THERAPEUTIC FOCUS:-

The patient was treated in Panchakarma unit.

The treatment comprised of *Majja Basti*, *Sarvang Dhara*, *Nasya*, *Karna Puran*, *Shirobasti*, *Shirodhara*.

2 cycles of *Majja Basti* (1 *Niruh Basti* followed by 3 *Majja Basti*) were

planned with gap of 15 days in between. For *Shiropadesh Snehan* purpose *Nasya* And *Karnapurana* were done in this period. The *Shirobasti* were targeted after resting period of 8 days after *Shirodhara* towards releasing the stress factor.

The schedule followed is given below :-

Table 1: Drug used for procedures.

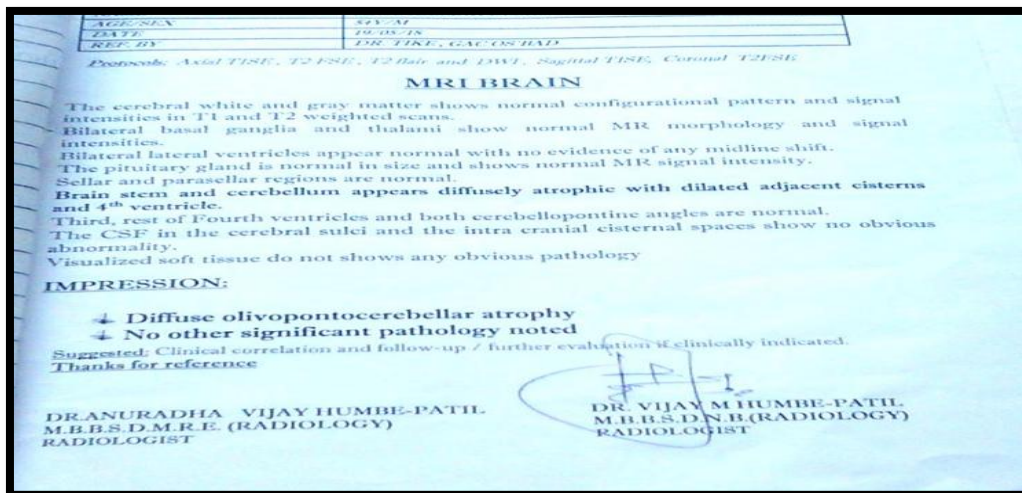
Procedures	Medication used
1. <i>Niruh Basti</i>	<i>Dashmoola + Erandmoola</i>
2. <i>Shirodhara</i>	<i>Jatamansi Oil + Bramhi Oil</i>
3. <i>Shirobasti</i>	<i>Jatamansi Oil + Bramhi Oil</i>
4. <i>Pratimarsh Nasya</i>	<i>Anu Taila</i>
5. <i>Karna Puran</i>	<i>Koshan Tila Taila</i>
6. <i>Sarvang Dhara</i>	<i>Koshan Tila Taila</i>

1. *Majja Basti With Niruh Basti* for 16days (2sets)
2. *Shiro Dhara* followed by *Shirobasti* for 15 days
3. *Pratimarsh Nasya* for 39 days
4. *Karnapurana* for 39 days
5. *Sarvang Dhara* for 39 days.

OUTCOME:-

Positive changes were seen as by comparing previous MRI reports that atrophy was arrested.

1. **MRI 19/05/2018** - MRI brain shows diffuse olivopontocerebellar atrophy.



Berg balance scale (BBS score) was improved from 24 to 41. Patient is now able to walk independently. Grip of upper limb was significantly improved. The patient was quiet comfortable despite the fact that allopathic medication has been totally weaned off.

The patient shows significant improvement after that treatment.

BERG BALANCE SCALE :-^[7]

Purpose- To test static and dynamic balance abilities of a person.

Method- Set of 14 simple task ranging; standing up from sitting position to standing on one foot.

The degree of success; Zero (unable) to Four (independent). Maximum score given is 56.

≤20	Wheelchair user
>20≤40	Walking with assistant
>40≤56	independent

DISCUSSION :-

‘Cerebellar Ataxia’ is made up of two words; Cerebellar means brain similar to Mastulunga or majja in ayurveda and Atrophy is similar to *Kshaya Awashtha* in Ayurveda. According to *Vyadhiviparit Chikitsa Sidhhanta Kshaya Pradhana Vyadhi* should be treated by *Bruhana Chikitsa*. *Chakrapani* considered *Mastulunga* as *Shirogat Sneha*.^[8] *Snehan* by various mode was the main principle of treatment also the principle of *Samanya Vishesh* was taken into consideration.

CONCLUSION :-

Cerebellar ataxia (*Majjakshaya*) diagnosed according to *Ayurvedic Nidan Panchak* can be treated with *Ayurvedic* principles. *Hetu & Samprapti Vichar* plays important role in the treatment of neurological disorders. In neurological disorders *Panchakarma* can help in faster recovery than only by *Shaman Chikitsa*. *Anukta Vyadhi Nidan* (Diagnosis) can be done by using modern diagnostic tools.

REFERENCES :-

1. Cerebellar ataxia, https://en.wikipedia.org/wiki/Cerebellar_ataxia
2. Jones TM et. Al. Treatment of Cerebellar Ataxia, Neurodegenerative disease management, vol.4 (5). <https://doi.org/10.2217/nmt.14.27>
3. Kenneth wang, Differential diagnosis and intervention in clinical neurology. <http://www.hunter.cuny.edu/pt/repository/files/clinical-neurology-papers-for-upload/Cerebellar%20Ataxia%20Paper.pdf>
4. *Sushrut. Ambikadattashastri. Sushrut samhita. Chikitsasthan. Kushthanidan adhyay 2/70. Chaukhamba Sankrit sansthan Varanasi;2009:321*
5. *Sushrut. Ambikadattashastri. Sushrut samhita. Sutrasthan. Kushthanidan adhyay 23/12. Chaukhamba Sankrit sansthan Varanasi;2009:321*
6. *Vagbhat. Bramhananda tripathi. Ashtang Hrudaya. Sutrasthan. Kusthswitrakruminidan adhyay 11/19. Chaukhamba sankrit pratishthan delhi; 2011:529*
7. https://www.physio-pedia.com/Berg_Balance_Scale
8. *Charak. Bramhanand tripathi. Charak samhita. Chikitsasthan. Kushthachikitsa adhyay 7/13. Chaukhamba surbharati prakashan Varanasi; 2014:302*

Cite this article:

"Ayurvedic management in cerebellar ataxia (Mastulungakshaya) : A case study."

Sunilkumar S. Yadav, Ashwini V. Mandle, Sachin G. Tike

Ayurline: International Journal of Research In Indian Medicine 2020; 4 (1) : 1- 5